

# The Liver

HST.035

Spring 2003

**The liver is designed to maintain  
body's chemical and metabolic  
homeostasis**

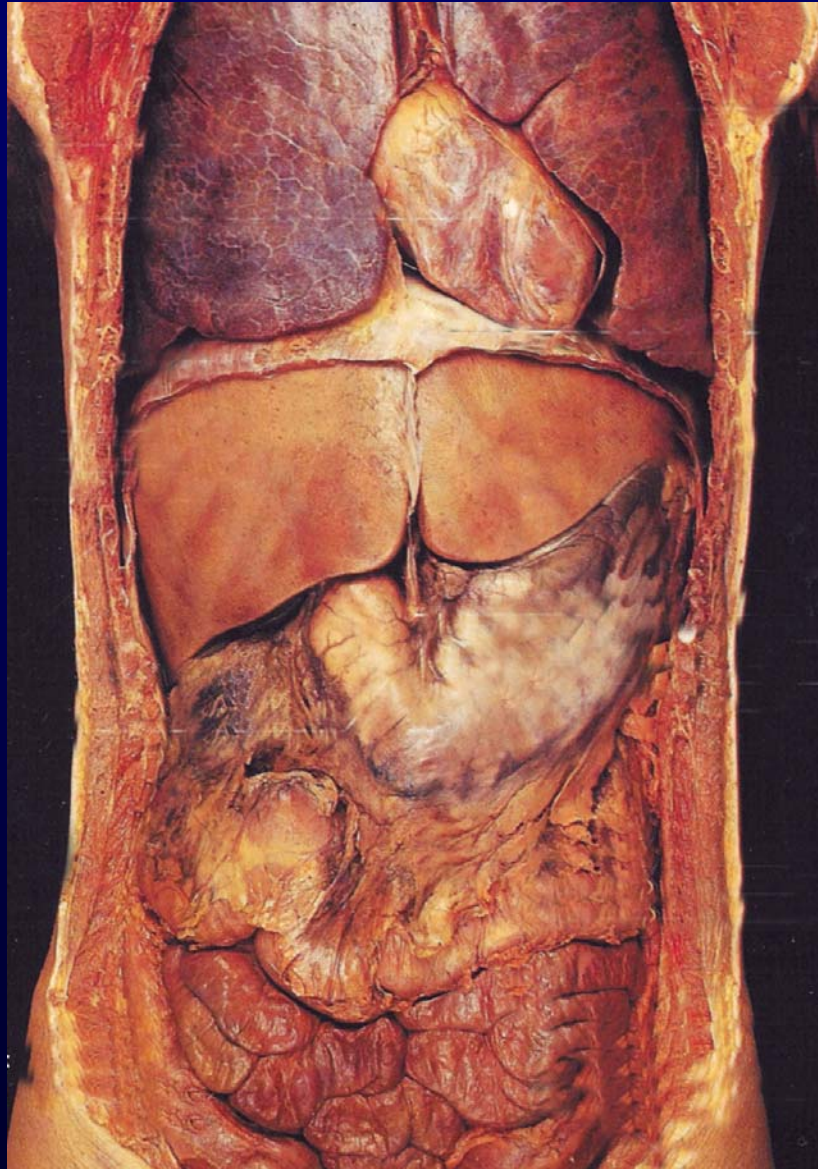
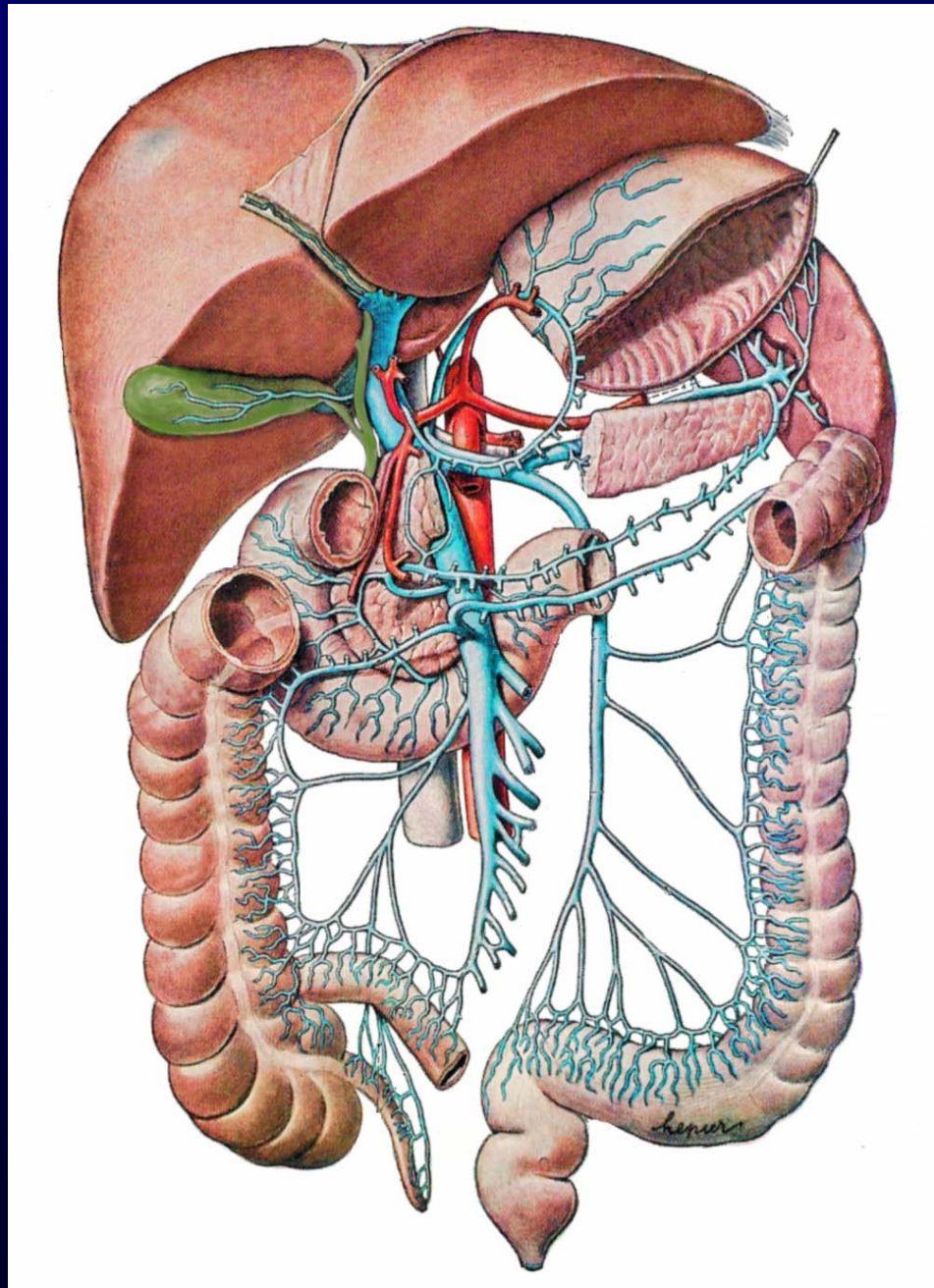
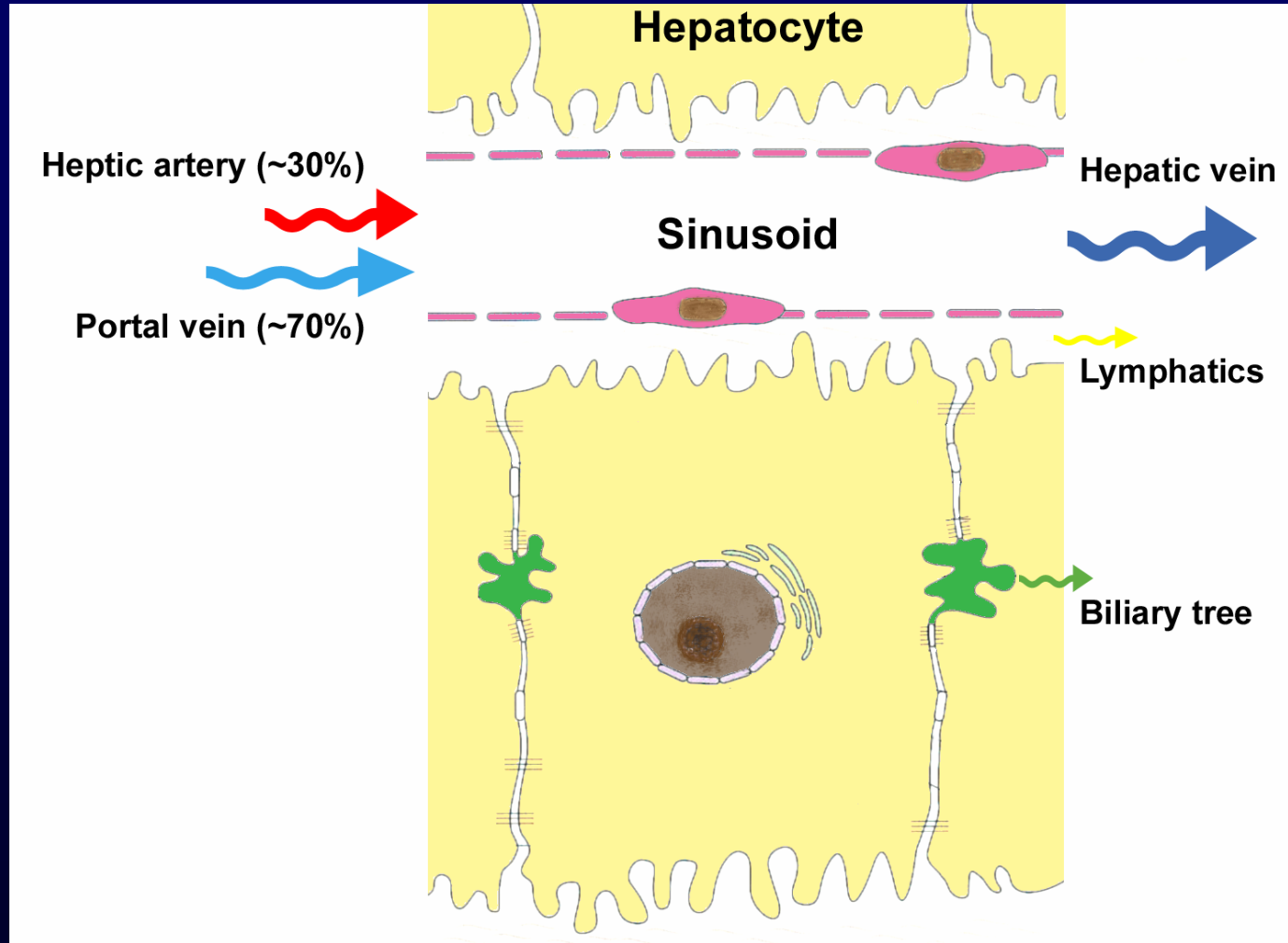


Image modified from Rohen and Yokochi, Color Atlas of Anatomy, Igaku-Shoin, 1988.

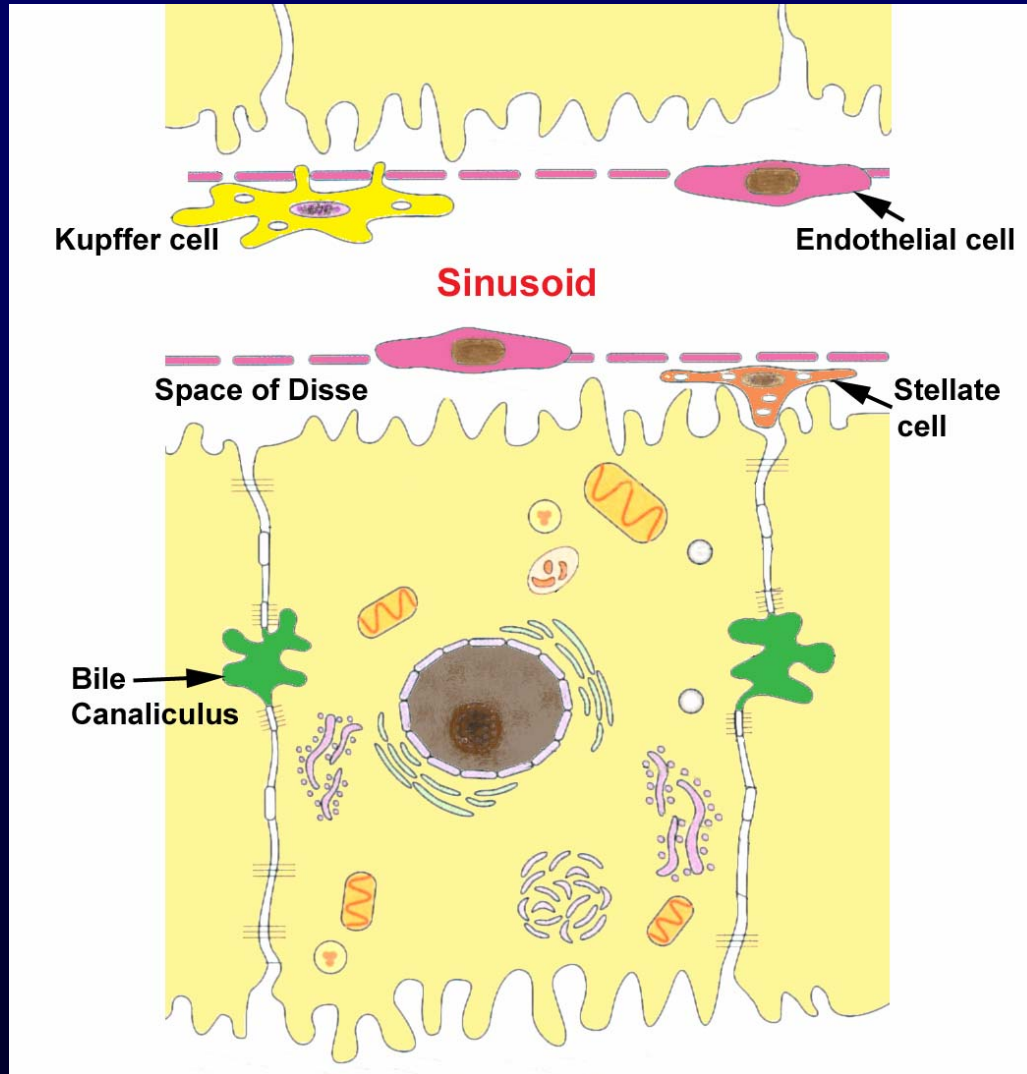


Modified image produced based on Clemente, Anatomy, Urban & Schwarzenberg, 1987.

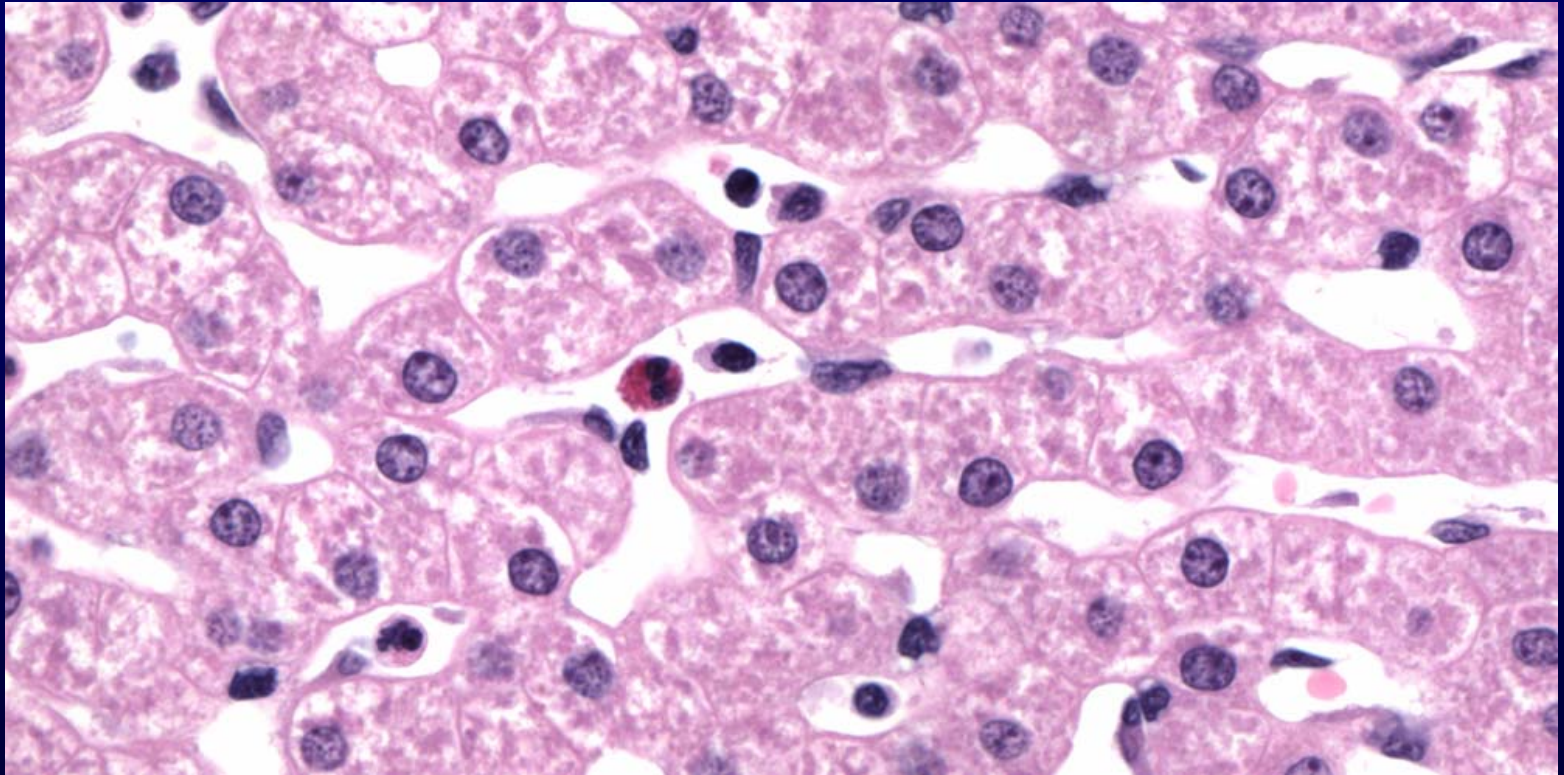
# Parenchymal Microcirculation



# Parenchymal Microanatomy



# Parenchymal Microanatomy

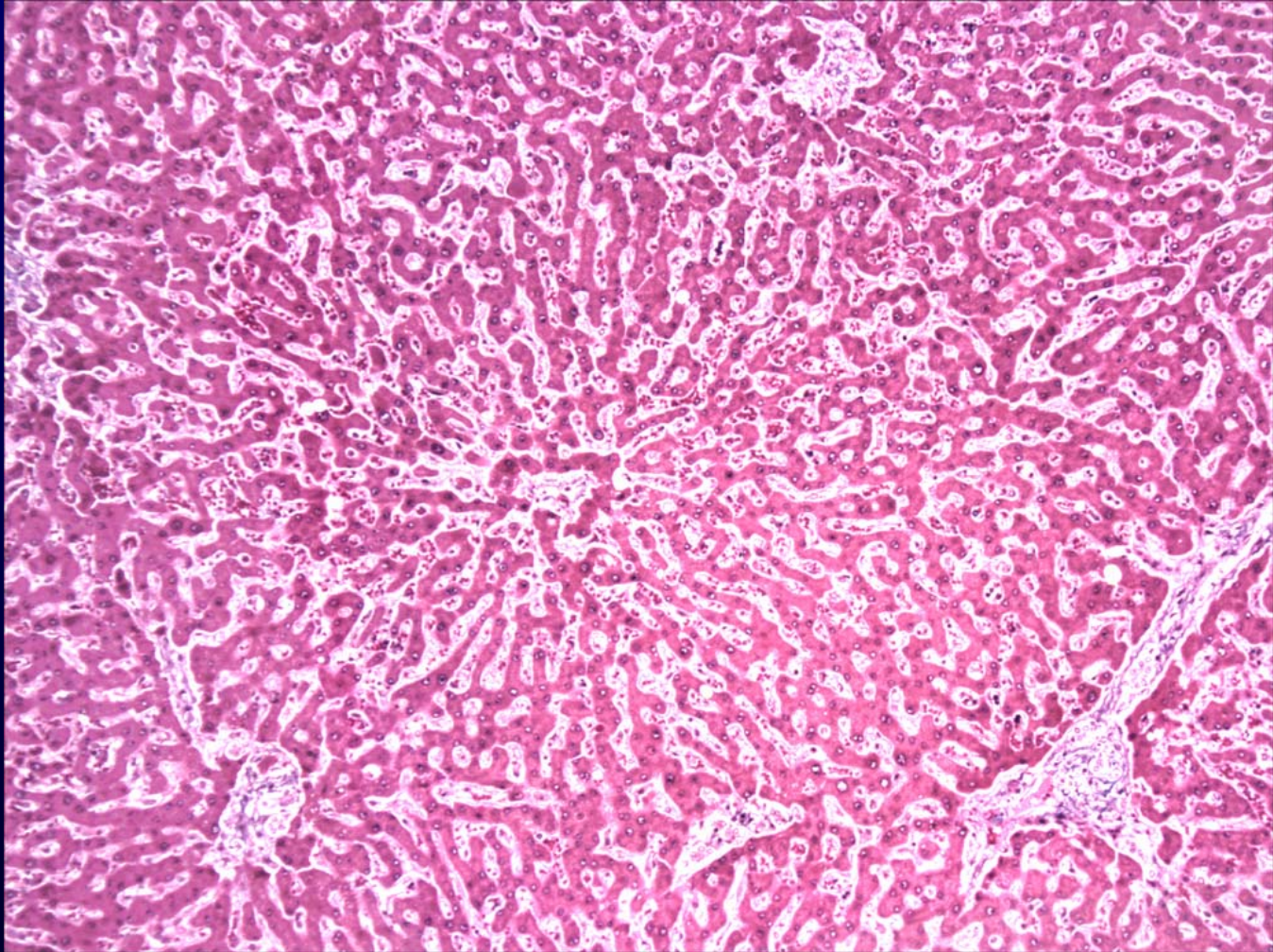


# Lobular Microanatomy

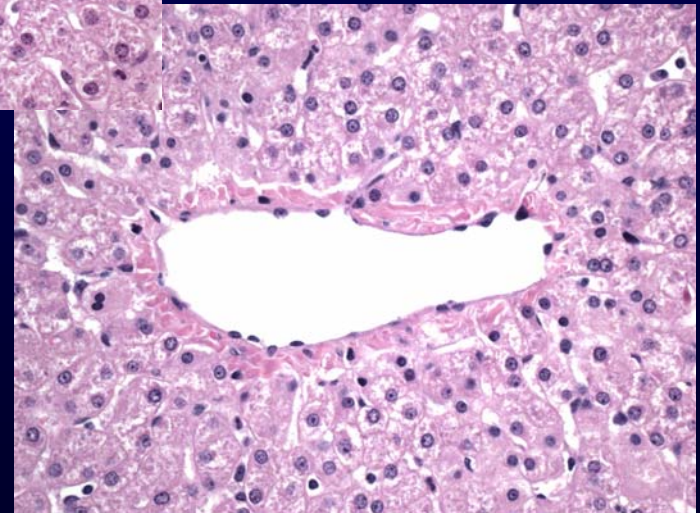
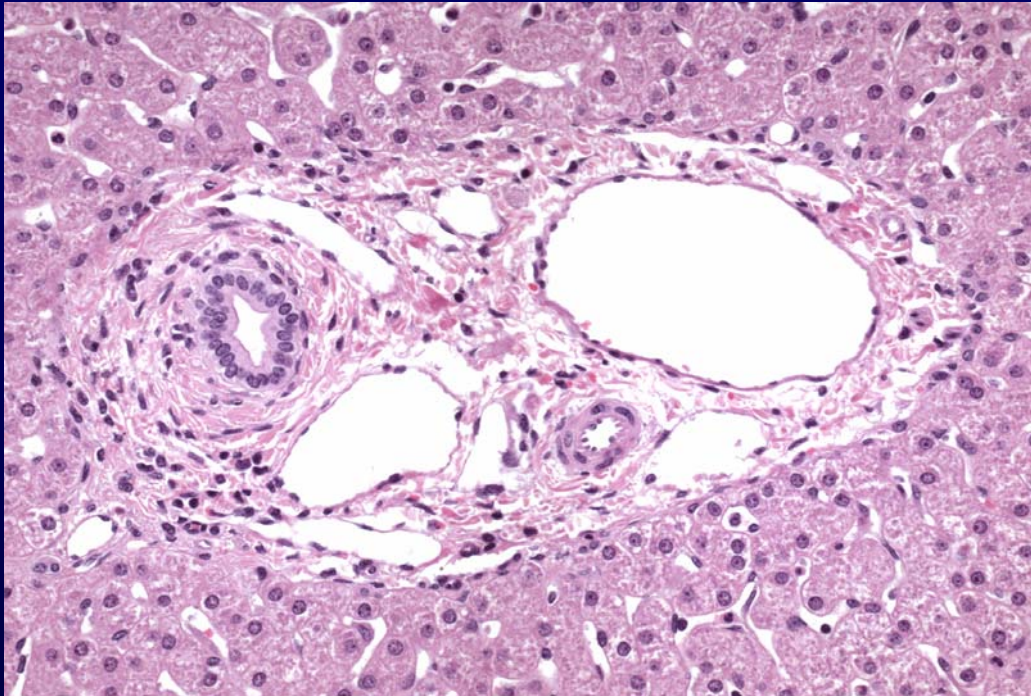
Please see Junqueira & Carneiro. *Basic Histology: Text and Atlas*. 10<sup>th</sup> edition. McGraw Hill. 2003. ISBN: 0071378294.



# Lobular Histology



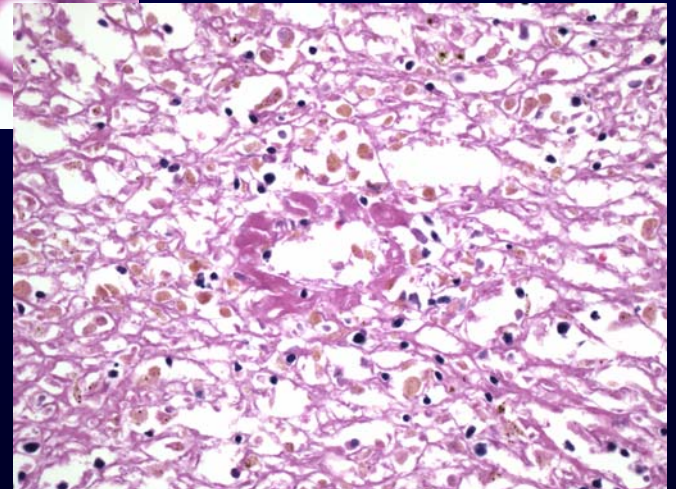
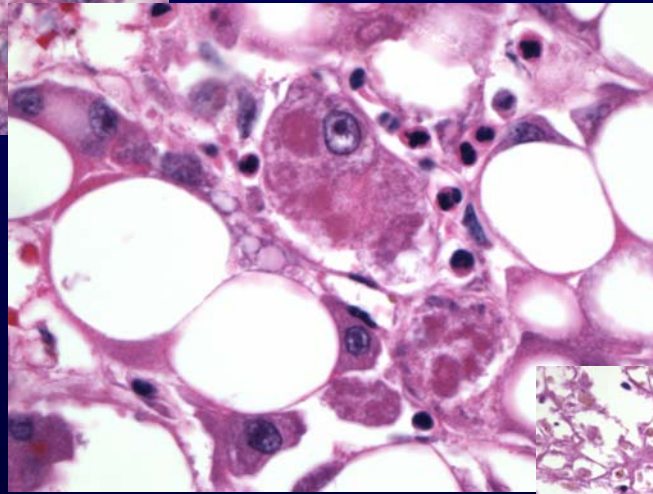
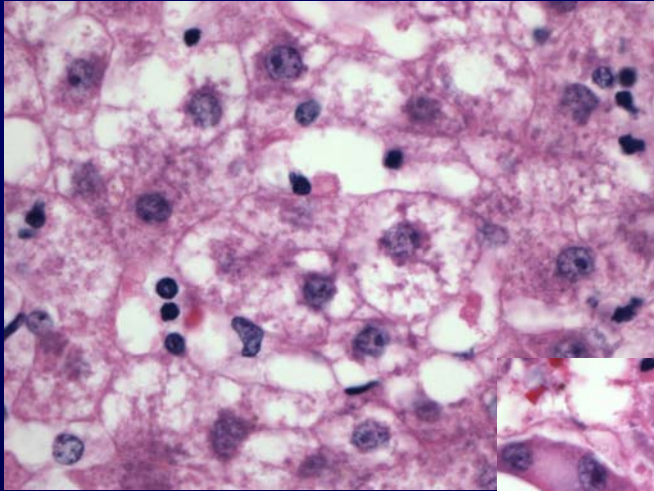
# Portal Tract and Central Vein



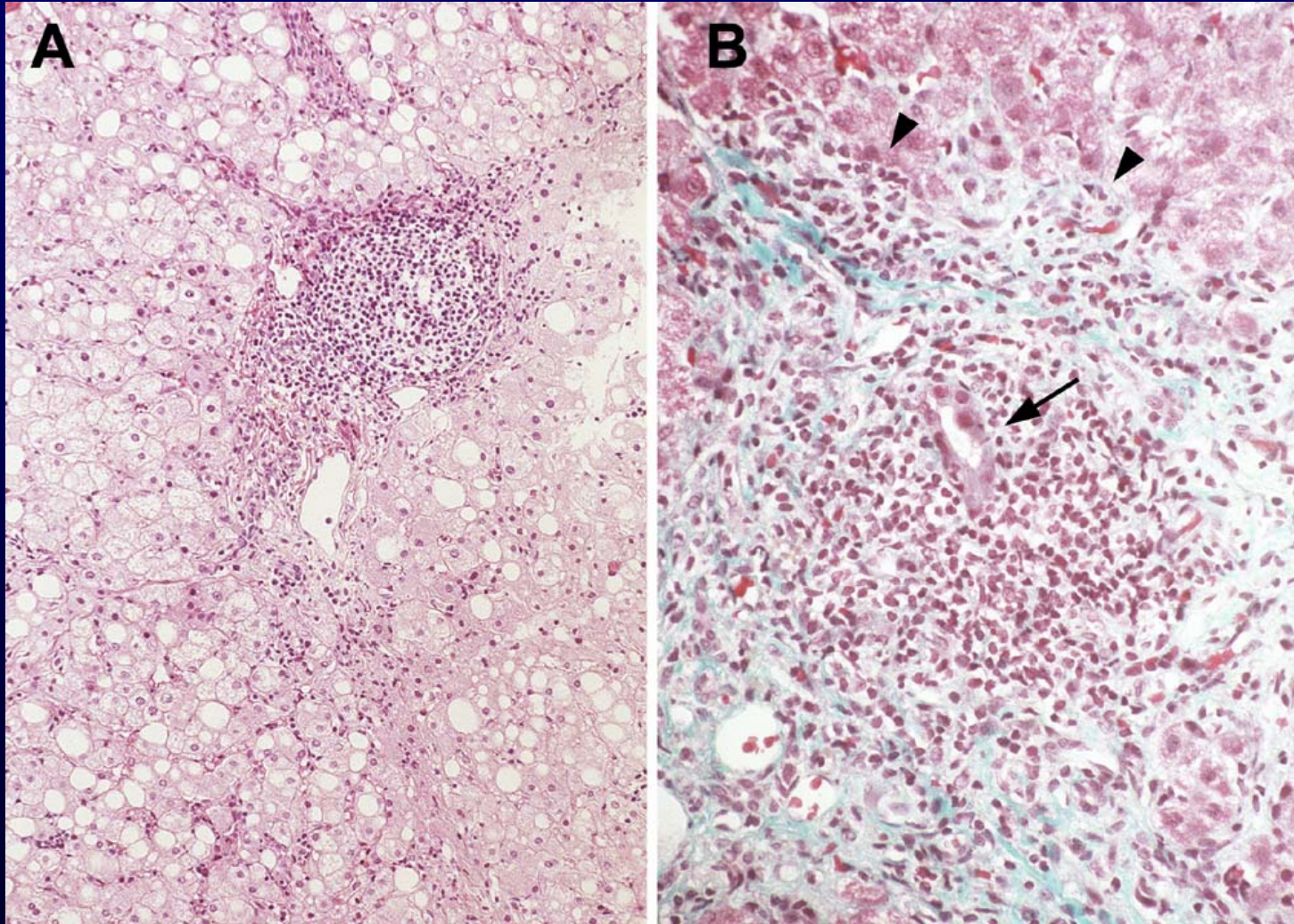
# Morphological Patterns of Hepatic Injury

- Hepatocellular degeneration and intracellular accumulation
  - *Ballooning and foamy degeneration*
  - *Steatosis*
- Necrosis and apoptosis
  - *Councilman bodies (apoptotic hepatocytes)*
  - *Zonal necrosis*
  - *Massive necrosis*
- Inflammation (hepatitis)
- Regeneration
- Fibrosis
  - *Cirrhosis*

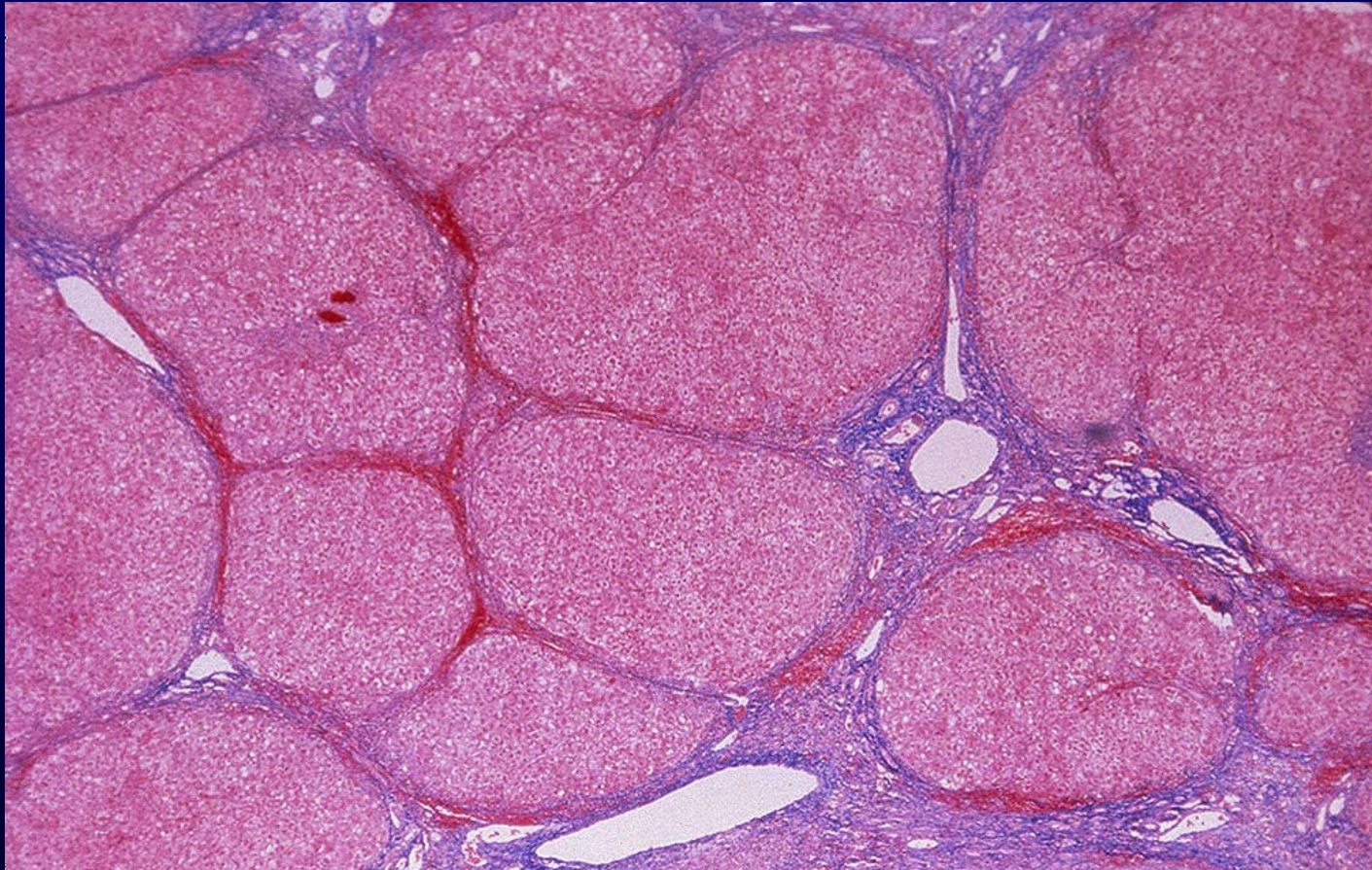# Morphological Patterns of Hepatic Injury: *Hepatocellular Damage*



# Morphological Patterns of Hepatic Injury: *Hepatitis*



# Morphological Patterns of Hepatic Injury: *Cirrhosis (Regeneration + Fibrosis)*



# Clinical Signs of Hepatic Injury

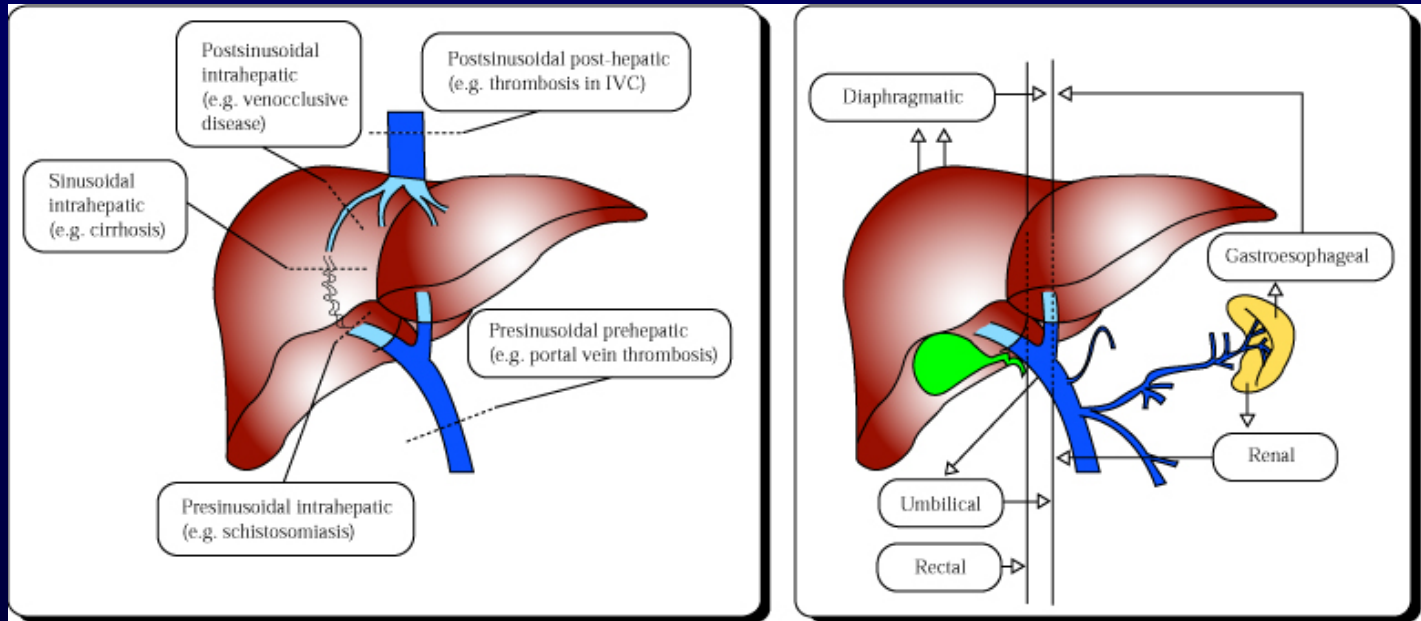
Please see O'Grady, John G. et. Al. *Comprehensive clinical hepatology*. Mosby, 2000. ISBN: 072343106X.

# Clinical Signs of Hepatic Injury

Please see O'Grady, John G. et. Al. *Comprehensive clinical hepatology*. Mosby, 2000. ISBN: 072343106X.



# Portal Hypertension and Venous Collaterals



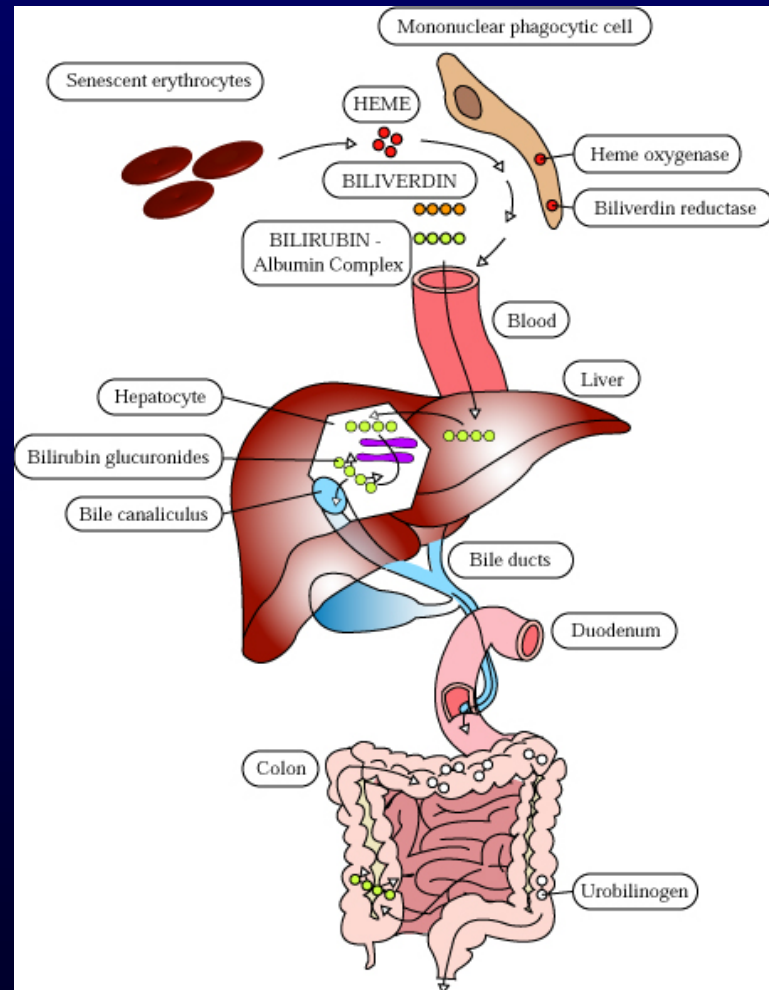
*Portal Hypertension → Varices*

# Clinical Signs of Hepatic Injury

Please see O'Grady, John G. et. Al. *Comprehensive clinical hepatology*. Mosby, 2000. ISBN: 072343106X.

# Bilirubin Metabolism and Elimination

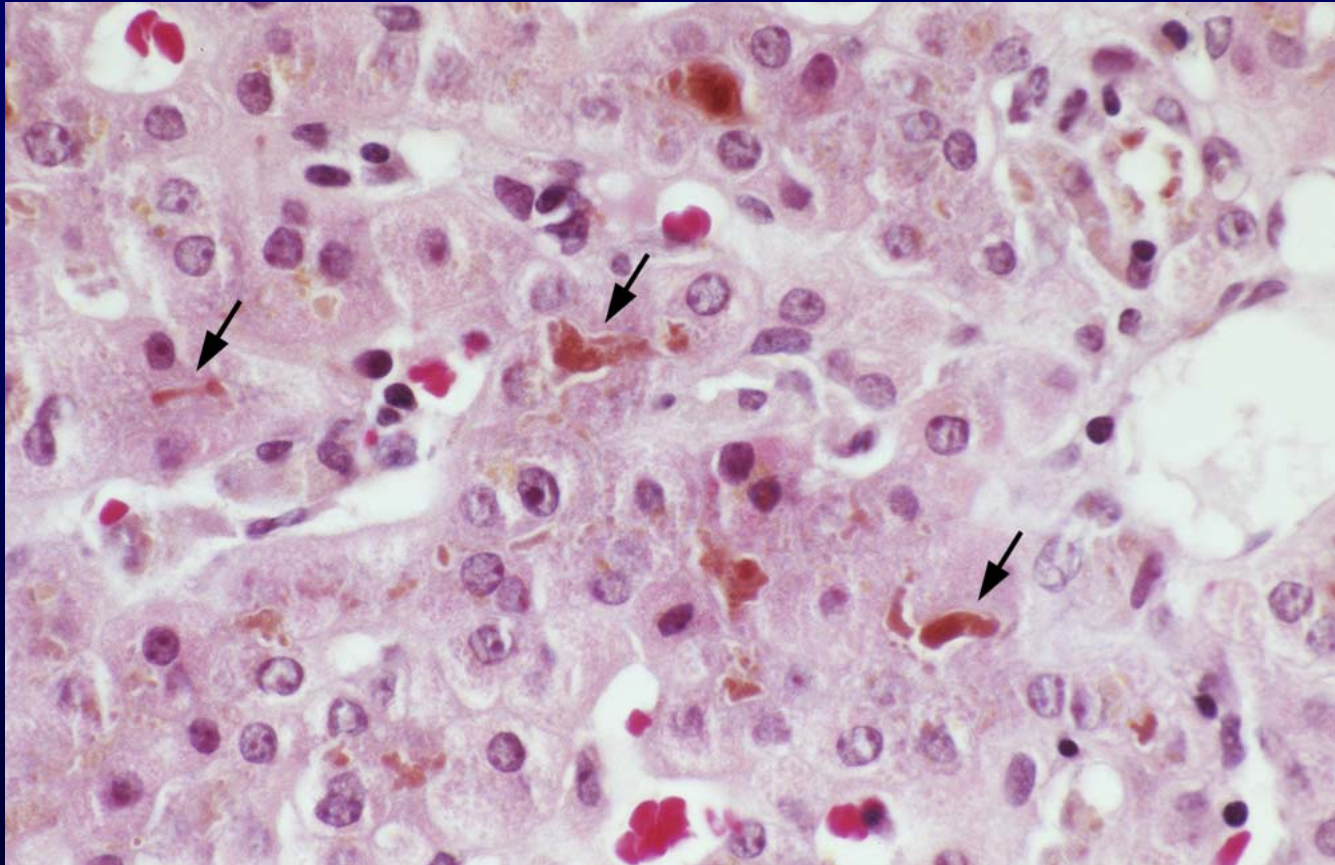
1. *Heme oxygenase* oxidizes heme to biliverdin
2. *Biliverdin reductase* reduces biliverdin to **unconjugated**, water-insoluble bilirubin, which is carried in blood bound to serum albumin
3. Carrier-mediated transport of unconjugated bilirubin into hepatocytes
4. Bilirubin is **conjugated** to glucuronic acids by uridine diphosphate glucuronyltransferase (UGT) and conjugated bilirubin is transported into bile canaliculi by MRP2
5. Intestinal bacteria deconjugate and breakdown bilirubin into colorless urobilinogens, which are primarily excreted in feces



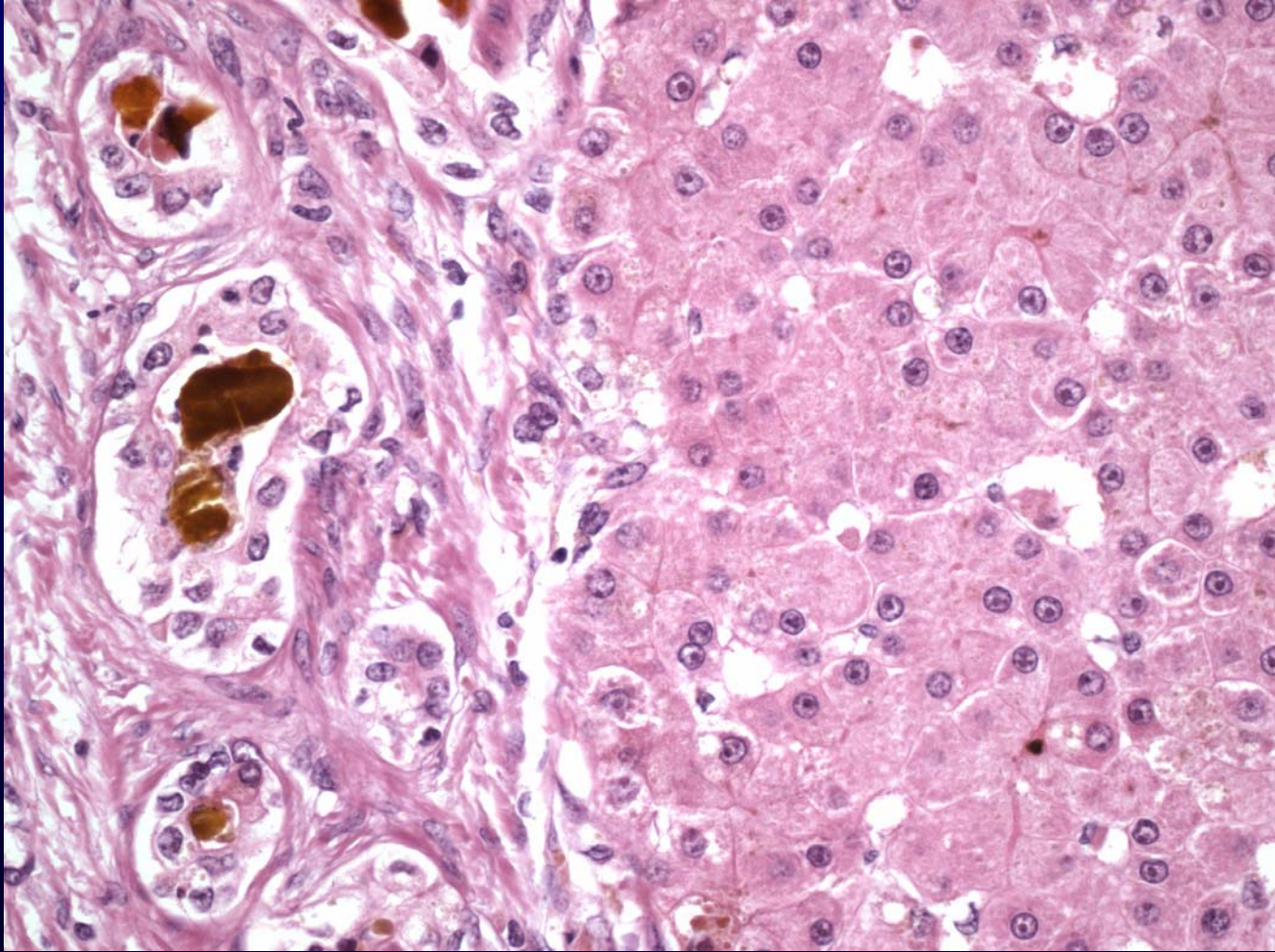
# Causes of Jaundice

- **Disorders of bilirubin production or metabolism**
  - Unconjugated:
    - Overproduction (hemolysis, ineffective hematopoiesis)
    - Decreased conjugation (newborns, Crigler-Najjar, Gilbert)
  - Conjugated:
    - Impaired canalicular transport (Dubin-Johnson)
- **Liver diseases**
  - Acute or chronic hepatocellular injury
  - “Intrahepatic cholestasis”
- **Obstruction of bile ducts (“extrahepatic cholestasis”)**
  - Gallstones
  - Other masses
  - Inflammation/infection

# Intrahepatic Cholestasis



# Extrahepatic Cholestasis



# **Viral Hepatitis**

# Hepatitis A

- The most common cause of viral hepatitis worldwide.
- Estimated 75,000 clinical cases/yr in the US.

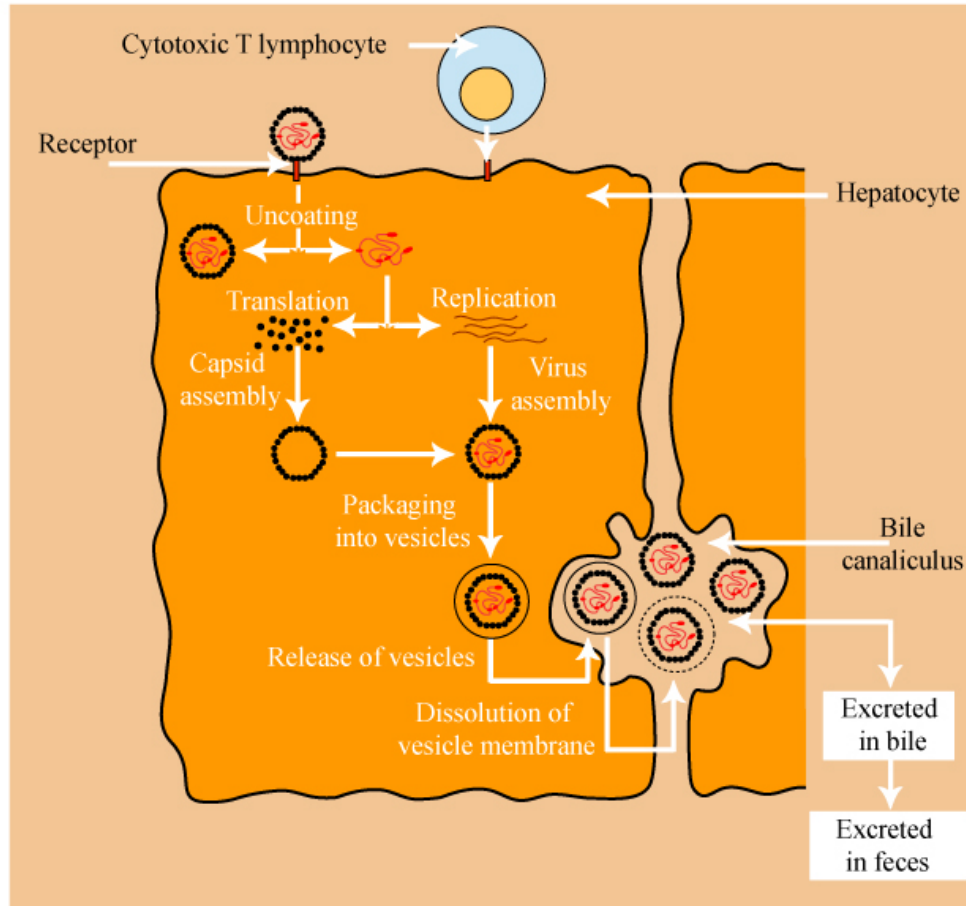
Please see O'Grady, John G. et. Al. *Comprehensive clinical hepatology*.  
Mosby, 2000. ISBN: 072343106X.



# Clinical Characteristics of Hepatitis A

Please see O'Grady, John G. et. Al. *Comprehensive clinical hepatology*. Mosby, 2000. ISBN: 072343106X.

# Pathogenesis of Hepatitis A



# Hepatitis B

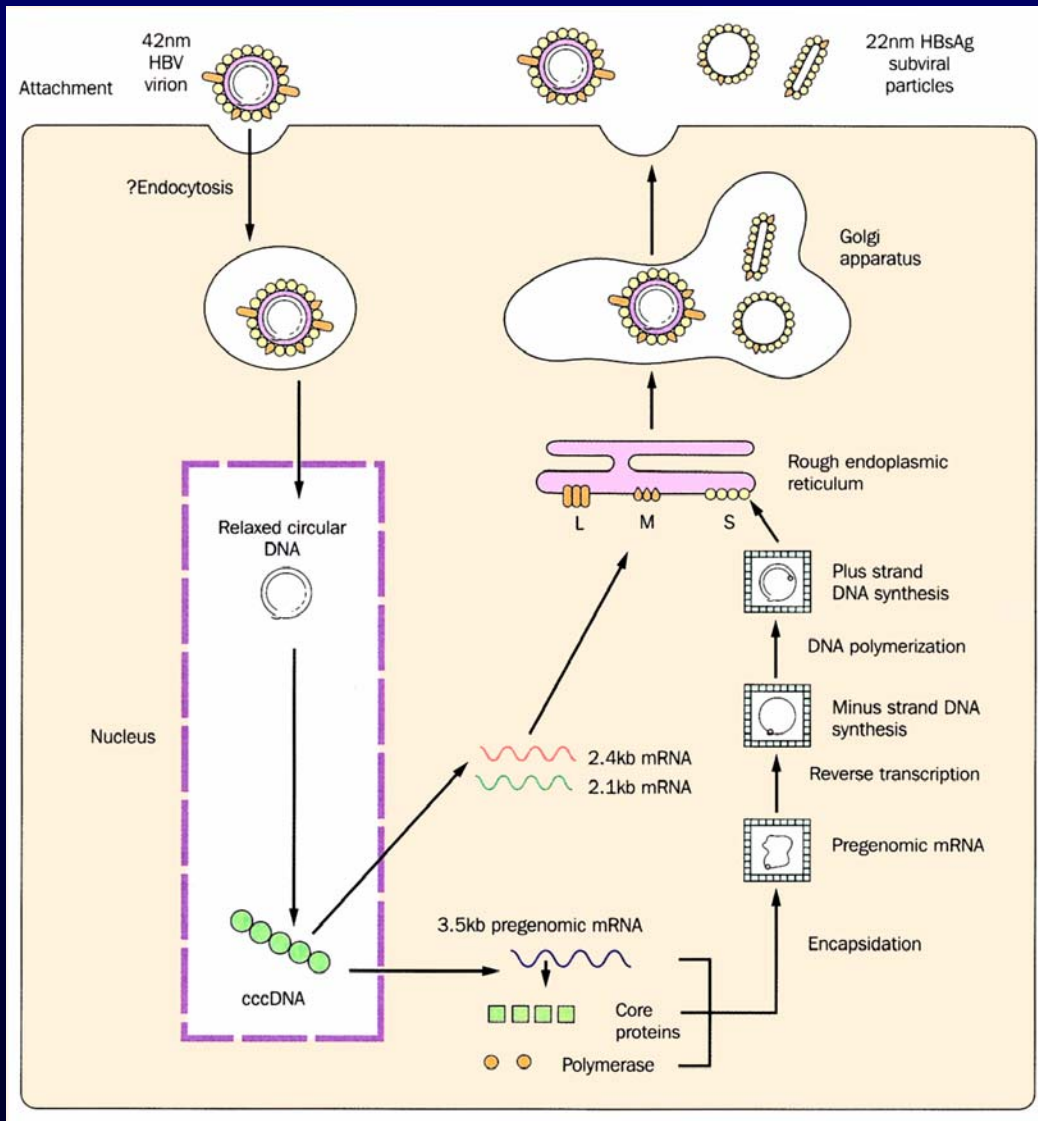
- ~300 million infected worldwide, of whom 250,000 die of complications.
- Sexual transmission is the major mode of spread in developed countries.
- Perinatal transmission occurs in 90% of infants born to HBeAg+ mothers.

Please see O'Grady, John G. et. Al. *Comprehensive clinical hepatology*. Mosby, 2000. ISBN: 072343106X.

# Clinical Outcomes of HBV Infection

Please see figure 19-9, pg. 858 of Cotran et al. *Robbins Pathological Basis of Disease*. 6th edition. WB Saunders 1999. ISBN: 072167335X.

# Lifecycle of HBV



# Hepatitis C

- The global prevalence of *chronic* HCV is ~3%.
- 4 million HCV carriers in US; 5 million in Europe.
- Transmission as a blood-borne pathogen.

Please see O'Grady, John G. et. Al. *Comprehensive clinical hepatology*.  
Mosby, 2000. ISBN: 072343106X.

# Clinical Outcomes of HCV Infection

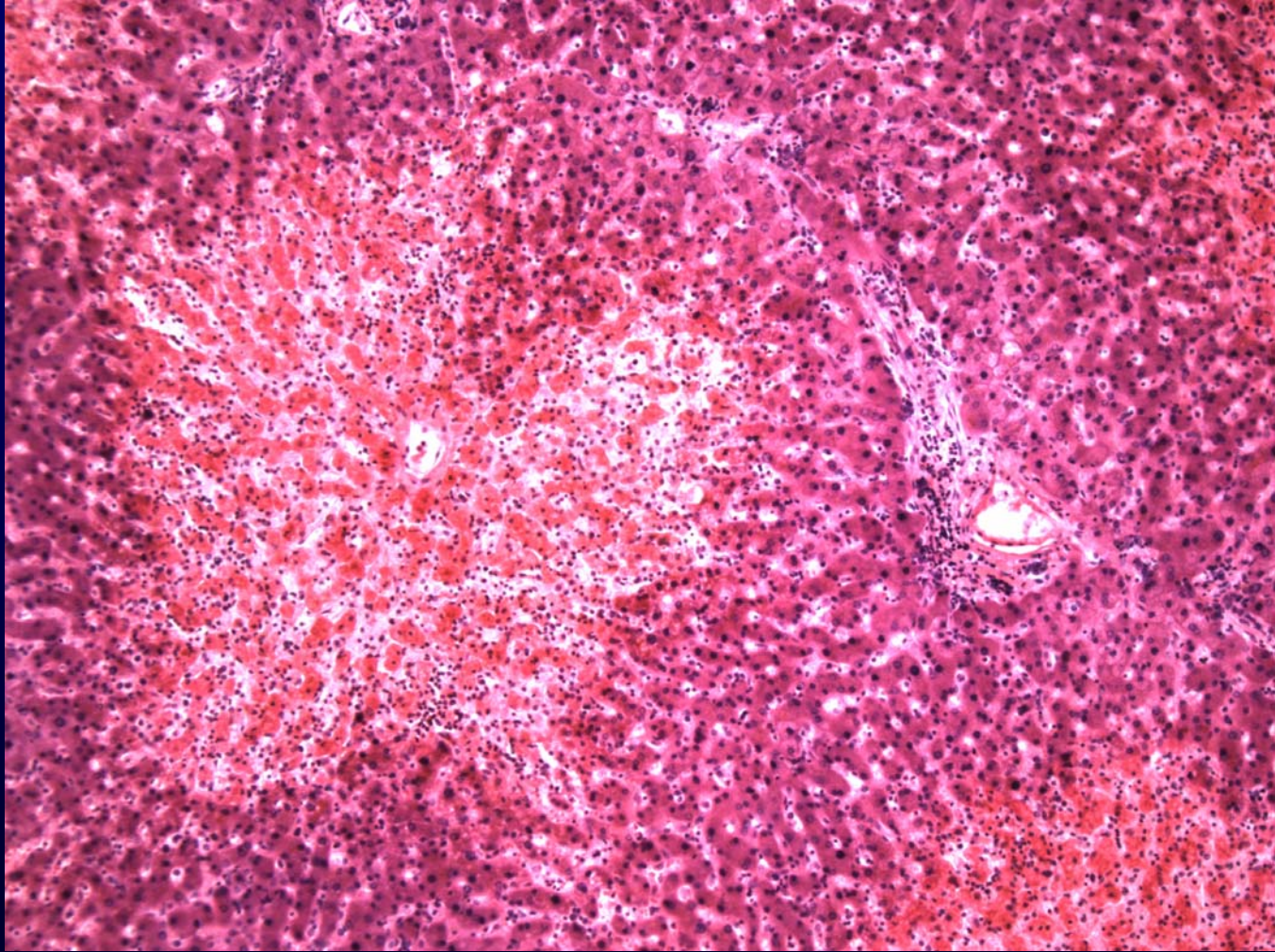
Please see figure 19-12, pg. 860 of Cotran et al. *Robbins Pathological Basis of Disease*. 6th edition. WB Saunders 1999. ISBN: 072167335X.

# Drug and Toxin-Induced Liver Disease

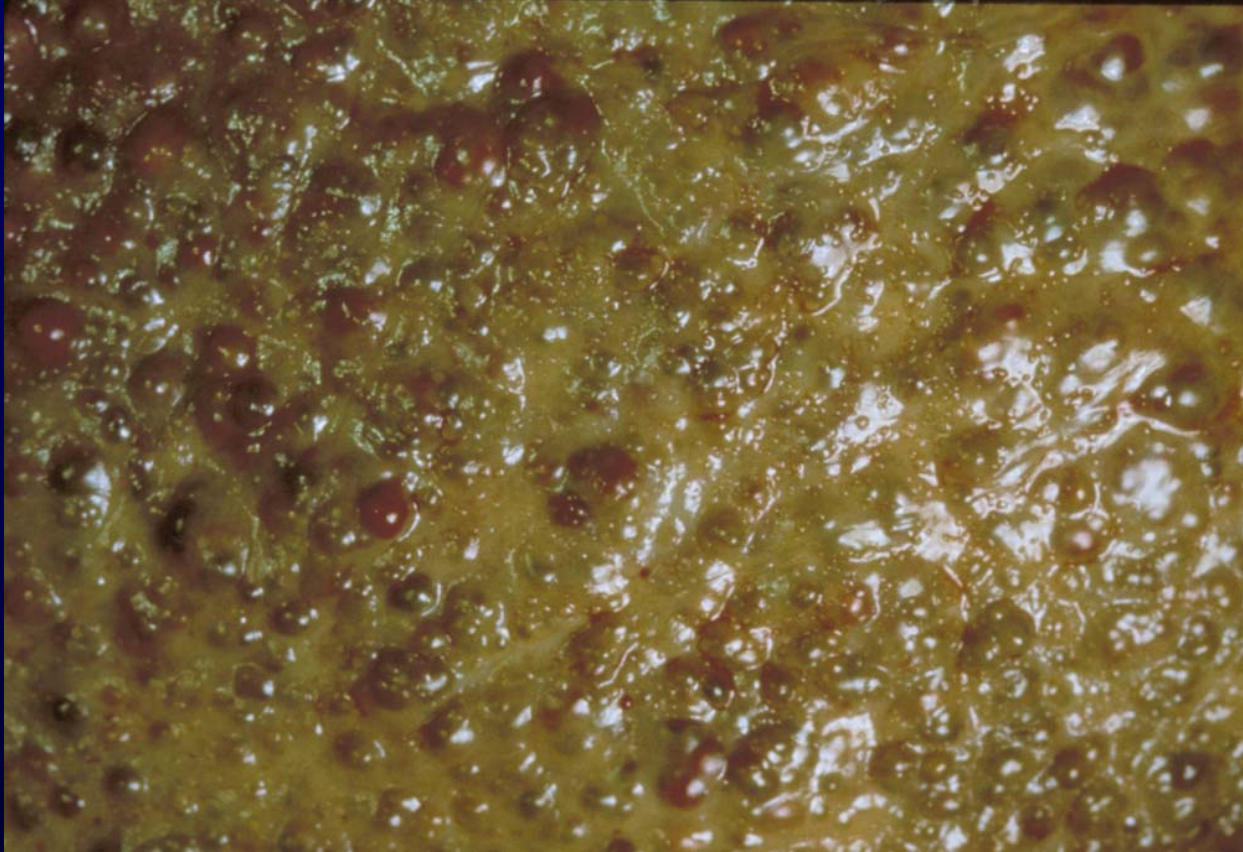
<b>Pattern of Damage</b>	<b>Example of Drugs</b>
Microvesicular steatosis	Tetracycline, ethanol, aspirin
Macrovesicular steatosis	Ethanol, methotrexate
Centrilobular necrosis	Tylenol, rifampin
Massive necrosis	Halothane, isoniazid
Hepatitis	Isoniazid, methyldopa
Fibrosis	Ethanol, methotrexate
Granulomas	Sulfonamides, quinine
Cholestasis	Chlorpromazine, steroids



# Drug and Toxin-Induced Liver Disease



# Alcoholic Liver Disease



# Alcoholic Liver Disease

